

Title: Association between Coronary Collaterals and Myocardial Viability in Patients with a Chronic Total Occlusion.

Authors: Stefan P. Schumacher, M.D; Henk Everaars, M.D; Wijnand J. Stuijzand, M.D; Jennifer W. Huynh, BSc; Pepijn A. van Diemen, M.D; Michiel J. Bom, M.D; Ruben W. de Winter, M.D; Ramon B. van Loon, M.D, PhD; Peter M. van de Ven, PhD; Albert C. van Rossum, M.D, PhD; Maksymilian P. Opolski, M.D, PhD; Alexander Nap, M.D, PhD; Paul Knaapen, M.D, PhD

DOI: 10.4244/EIJ-D-19-01006

Citation: Schumacher SP, Everaars H, Stuijzand WJ, Huynh JW, van Diemen PA, Bom MJ, de Winter RW, van Loon RB, van de Ven PM, van Rossum AC, Opolski MP, Nap A, Knaapen P. Association between Coronary Collaterals and Myocardial Viability in Patients with a Chronic Total Occlusion. *EuroIntervention* 2020; Jaa-745 2020, doi: 10.4244/EIJ-D-19-01006

Manuscript submission date: 06 November 2019

Revisions received: 13 January 2020, 1 February 2020

Accepted date: 27 February 2020

Online publication date: 03 March 2020

Disclaimer: This is a PDF file of a "Just accepted article". This PDF has been published online early without copy editing/typesetting as a service to the Journal's readership (having early access to this data). Copy editing/typesetting will commence shortly. Unforeseen errors may arise during the proofing process and as such Europa Digital & Publishing exercise their legal rights concerning these potential circumstances.

Association between Coronary Collaterals and Myocardial Viability in Patients with a Chronic Total Occlusion

Stefan P. Schumacher, MD¹, Henk Everaars, MD¹, Wijnand J. Stuijtzand, MD¹, Jennifer W. Huynh, BSc¹, Pepijn A. van Diemen, MD¹, Michiel J. Bom, MD¹, Ruben W. de Winter, MD¹, Ramon B. van Loon, MD, PhD¹, Peter M. van de Ven, PhD², Albert C. van Rossum, MD, PhD¹, Maksymilian P. Opolski, MD, PhD³, Alexander Nap, MD, PhD¹, Paul Knaapen, MD, PhD¹

¹Department of Cardiology, Amsterdam Cardiovascular Sciences, ²Department of Epidemiology and Biostatistics, Amsterdam UMC, Vrije Universiteit Amsterdam, Amsterdam, the Netherlands

³Department of Interventional Cardiology and Angiology, Institute of Cardiology, Warsaw, Poland.

Short title: Collaterals and viability in patients with a CTO

The authors have no conflicts of interest to declare.

Corresponding author:

Paul Knaapen, MD, PhD

Department of Cardiology, Amsterdam UMC, location Vrije Universiteit Amsterdam

De Boelelaan 1117, Suite 4D36, 1081 HV Amsterdam, The Netherlands

Email: p.knaapen@amsterdamumc.nl/ Phone:+31204440123/ Fax:+31204442446

Disclaimer : As a public service to our readership, this article -- peer reviewed by the Editors of EuroIntervention - has been published immediately upon acceptance as it was received. The content of this article is the sole responsibility of the authors, and not that of the journal

ABSTRACT

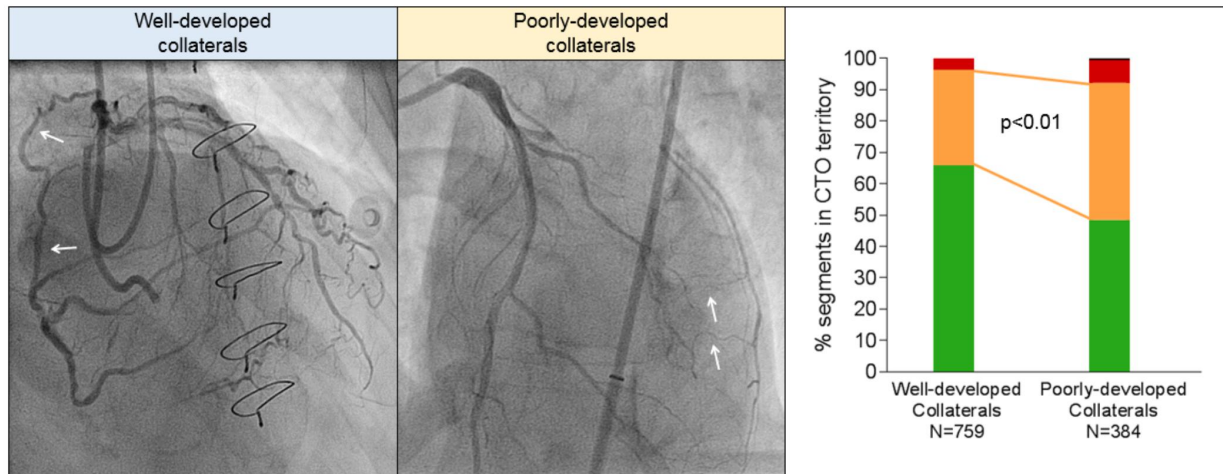
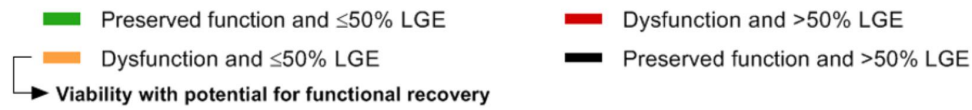Aims: This study evaluated associations between coronary collaterals and myocardial viability assessed by quantitative cardiac magnetic resonance (CMR) imaging in patients with a chronic coronary total occlusion (CTO).

Methods and results: 218 patients with a CTO who underwent CMR between 2013-2018 were included. A concomitant collateral connection (CC) score 2 and Rentrop grade 3 defined well-developed collaterals in 146 (67%) patients, whereas lower CC scores or Rentrop grades characterized poorly-developed collaterals. Dysfunctional myocardium ($<3\text{mm}$ segmental wall thickening (SWT)) and $\leq 50\%$ late gadolinium enhancement defined viability. Extensive scar (LGE $>50\%$) was observed in only 5% of CTO segments. In the CTO territory, SWT was higher (3.72 ± 1.51 vs. $3.05\pm 1.60\text{mm}$, $p<0.01$) and extent of scar was lower ($7.0 [0.1-16.7]$ vs. $13.1\% [2.8-22.2]$, $p=0.048$) in patients having well-developed vs. poorly-developed collaterals. Viability was more prevalent in CTO segments among patients with poorly-developed vs. well-developed collaterals (44% vs. 30% of segments, $p<0.01$), predominantly due to higher prevalence of dysfunctional myocardium (51% vs. 34% of segments, $p<0.01$) in the poorly-developed collateral group.

Conclusions: The infarcted area in myocardium subtended by a CTO is generally limited. Well-developed collaterals are associated with less myocardial scar and enhanced preserved function. However, viability was regularly present in patients with poorly-developed collaterals.

Classifications: Stable angina; Non-invasive imaging; Chronic coronary total occlusion;

CMR-derived viability with potential for functional recovery is regularly present in myocardium supplied by poorly-developed collaterals in patients with a CTO



CONDENSED ABSTRACT

The present study evaluated associations between coronary collaterals and myocardial viability assessed by quantitative cardiac magnetic resonance (CMR) imaging in 218 patients with a chronic coronary total occlusion (CTO). The infarcted area in myocardium subtended by a CTO was generally limited. Well-developed collaterals were associated with less myocardial scar and enhanced preserved function. However, viability with potential for functional recovery was regularly present in patients with poorly-developed collaterals. These results suggest that patients with a CTO should not be repulsed from considerations for CTO revascularization based on the presence of poorly-developed collaterals or a CTO artery-related history of MI.

ABBREVIATIONS

CC	collateral connection
CMR	cardiac magnetic resonance
CTO	chronic coronary total occlusion
FDG PET	fluorine-18-deoxyglucose positron emission tomography
GEE	generalized Estimating Equations
LGE	late gadolinium enhancement
LV	left ventricle
LVEF	left ventricular ejection fraction
MI	myocardial infarction
PCI	percutaneous coronary intervention
PD	poorly-developed
SWT	segmental wall thickening
WD	well-developed

INTRODUCTION

Randomized trials evaluating the benefit of chronic coronary total occlusion (CTO) percutaneous coronary intervention (PCI) upon medical therapy on patient' health status and prognosis have shown conflicting results leading to an ongoing debate regarding judicious patient selection for CTO revascularization[1,2]. Guidelines advocate viability assessment, next to evaluation of invalidating symptoms and ischemia detection, to serve as one of the pillars in patient selection for CTO revascularization[3]. A hampered regional and global functional recovery after CTO PCI in prior studies may be due to a lack of viability (dysfunctional but viable myocardium) demonstration before revascularization[4,5]. Although there is a paucity of data, it has been hypothesized that the degree of collateral development on invasive coronary angiography correlates with the extent of myocardial infarction (MI) and viability[6,7]. Aim of the present study was to evaluate the association between coronary collaterals and viability as defined by cardiac magnetic resonance imaging (CMR) in patients with a CTO.

METHODS

Study design and participants

Patients presenting with a CTO and evaluated with CMR between 2013-2018 in a dedicated CTO PCI centre (Amsterdam University Medical Centre, Vrije Universiteit Amsterdam) were prospectively recruited. Exclusion criteria were a non-occluded bypass graft on the CTO artery, signs of microvascular obstruction or non-ischemic cardiomyopathy on CMR, and insufficient image quality for both cine and LGE analysis. Angiographic complexity and location of the CTO were both no reason to exclude patients from evaluation by CMR. A documented history of MI was defined as Q-wave MI or non-Q-wave MI depending on the presence of pathological

Q-waves on the electrocardiogram. The study was approved by the institutional Medical Ethics Review Committee and all patients provided written informed consent.

Angiographic characteristics

Angiographic characteristics on invasive coronary angiography were scored by an expert observer (SPS) using a monoplane cardiovascular X-ray system (Allura Xper FD 10/10; Philips Healthcare, Best, The Netherlands). A CTO was defined as a luminal occlusion in a native coronary artery for an estimated time of ≥ 3 months with no or minimal contrast penetration through the lesion (Thrombolysis in Myocardial Infarction flow grade 0 or 1). Collaterals supplying the vascular territory of the CTO were graded according to the collateral connection (CC) score as no visible connection (CC0), thread-like connection (CC1) or side branch-like connection (CC2)[8]. The Rentrop gradation for collateral flow was scored as no contrast filling of collaterals (grade 0), filling of collaterals without epicardial filling of the CTO artery (grade 1), partial epicardial filling of the CTO artery (grade 2), and complete epicardial filling of the CTO artery (grade 3)[8]. A concomitant CC2 score and Rentrop grade 3 defined the presence of well-developed (WD) collaterals in a patient, whereas collaterals were considered poorly-developed (PD) if the CC score was < 2 or the Rentrop grade < 3 [7].

CMR imaging acquisition and analysis

All CMR images were obtained on a 1.5-T scanner (Magnetom Avanto, Siemens Healthineers, Erlangen, Germany). A detailed description of acquisition techniques and CMR parameters are described in the supplementary materials. Image analysis was performed by an experienced observer (HE) blinded to clinical and angiographic data, using commercially available software (QMass v7.6, Medis medical imaging systems, Leiden, the Netherlands). Left ventricle (LV) volumes and ejection fraction (LVEF) were calculated from cine images. In addition, the LV was divided into 16 segments (true apex not included) and vascular territories according to the

Disclaimer : As a public service to our readership, this article -- peer reviewed by the Editors of EuroIntervention - has been published immediately upon acceptance as it was received. The content of this article is the sole responsibility of the authors, and not that of the journal

AHA segmentation model, accounting for coronary dominance[9]. Segmental wall thickening (SWT), defined as absolute difference between end-diastolic and end-systolic wall thickness, was calculated from short-axis cine images for each segment and as a mean for the entire CTO territory. Dysfunctional myocardium was defined as SWT <3mm[10]. Infarct size was calculated from late gadolinium enhancement (LGE) images and was expressed as percentage of the LV. Additionally, percentage scar was calculated for each segment and as a mean for the entire CTO territory, in which 0%, ≤50% and >50% LGE defined absence of, limited and extensive scar, respectively[11]. Previously, interobserver and intraobserver variabilities of these SWT and LV scar analyses from the same institute were reported to be 0.1±0.7 and 0.0±0.4mm and 1.2±4.1g and 0.8±1.6g[12]. As representative of myocardium with potential to functionally recover after revascularization, viability was defined as dysfunctional myocardium without extensive scar[6,11].

Statistical analyses

Normally distributed data are presented as mean ± standard deviation and compared using the independent-samples T-test. Non-normally distributed continuous data are presented as median [interquartile range] and compared using the Mann-Whitney U test. Categorical data are presented with numbers (percentages) and analysed using a Fisher's exact test. Proportion of CTO segments with no or limited scar, dysfunction or viability were compared between groups using Generalized Estimating Equations (GEE) for binary data. A logistic link was used together with an unstructured working correlation matrix to account for possible dependency between outcome measured in segments in the CTO territory of the same individual. When the overall effect for comparing ≥2 groups was significant, Bonferroni correction was applied for posthoc pairwise comparisons between groups. To test whether proportion of segments with viability was different between patients with WD and PD collaterals and whether differences

depended on subgroups based on diagnosis of prior MI in the CTO territory, we first fitted a GEE model with viability (yes/no) as the outcome and degree of collateral development (WD or PD), subgroup, and their two-way interaction as independent variables. A single overall GEE model was used to ensure that the same working correlation matrix estimate (based on all vessels) was used for all comparisons. Post-hoc tests based on this GEE model were then used to check for differences between WD and PD collaterals within each of the subgroups based on prior MI diagnosis. A Bonferroni correction was to account a separate comparison to be made for each of four subgroups. A level of $p < 0.05$ was considered significant. Statistical analyses were performed using SPSS software (IBM SPSS Statistics 22.0, Chicago, IL).

RESULTS

Patient population

A total of 218 out of 250 consecutive patients with a CTO and evaluated by CMR imaging were included for analysis. Sixteen patients were excluded because of a non-occluded bypass graft on the CTO artery, 7 because of signs of non-ischemic cardiomyopathy and 5 due to the presence of microvascular obstruction on CMR. In 4 patients, both cine and LGE images were of insufficient quality. Baseline clinical and angiographic characteristics of patients with WD (N=146, 67%) and PD (N=72, 33%) collaterals are presented in table 1 and supplementary table 1 and 2. The intraobserver and interobserver agreement of angiographic classification of collaterals to WD or PD in 44 (20%) randomly chosen patients was 86% (Cohen's kappa=0.65, 95% CI 0.40-0.89) and 80% (Cohen's kappa=0.57, 95% CI 0.33-0.81), respectively.

Relationships between myocardial infarction, function and collaterals

In 147 patients without documented history of MI in the CTO territory, LGE analysis demonstrated myocardial scar in 112 (76%) CTO territories. In total, 183 (84%) patients had

myocardial scar in the CTO region, with no difference in the prevalence of scar between patients with WD and PD collaterals (122 (84%) vs. 61 (85%) patients, $p=1.00$). Median percentage scar tissue in the CTO territory, however, was lower in patients with WD collaterals ($p=0.048$, figure 1a). A normal LV function ($LVEF >55\%$), mild dysfunction ($LVEF >40-55\%$), moderate dysfunction ($LVEF >30-40\%$) and severe dysfunction ($LVEF \leq 30\%$) was observed in 62 (29%) 104 (48%), 29 (13%), 21 (10%) patients, respectively. Mean LVEF was higher and LV end-diastolic and end-systolic volumes were smaller in patients with WD collaterals compared to patients with PD collaterals ($p=0.02$, $p=0.047$ and $p=0.03$, respectively, table 2). Mean SWT in the CTO territory was higher in patients with WD collaterals ($p<0.01$, figure 1b). Patients with multivessel disease had more scar tissue, larger LV volumes and worse LV function (supplementary table 3) compared to patients with single vessel disease. Case examples of patients with WD and PD collaterals are demonstrated in figure 2. The amount of scar tissue in the LV and CTO territory was inversely correlated with LVEF and mean SWT in the CTO territory (figure 3a-b).

Myocardial scar, dysfunction and viability in CTO territory-related segments

Absence or $\leq 50\%$ LGE was observed in 1085 out of 1143 (95%) segments in the CTO territory. Dysfunctional myocardium was present in 455 (40%) segments, with the other 688 (60%) demonstrating preserved function. Extent of scar and SWT in CTO segments were inversely correlated (figure 3c). Viability, representing dysfunctional myocardium without extensive scar, was present in 399 (35%) CTO segments. As demonstrated in figure 4a-4b and supplementary table 4, CTO-related segments were analysed in all patients and in patients stratified according to documented CTO vessel-related history of MI and presence of scar in the CTO territory on CMR imaging. In patients with WD collaterals, the prevalence of no or limited scar was higher compared to patients with PD collaterals (731 out of 759 (96%) vs. 354

out of 384 (92%) segments, $p<0.01$), although differences were small. Myocardium was dysfunctional in a substantial higher number of segments in patients with PD collaterals compared to patients with WD collaterals (196 out of 384 (51%) vs. 259 out of 759 (34%) segments, $p<0.01$). As a consequence, viability was present in more segments among patients with PD collaterals compared to patients with WD collaterals (168 out of 384 (44%) vs 231 out of 759 (30%) segments, $p<0.01$, figure 4c-4d). In addition, more CTO segments were dysfunctional in patients with multivessel disease compared to patients with single vessel disease, leading to a higher amount of segments with viability (supplementary table 3).

DISCUSSION

The present study is the largest to date evaluating the extent of myocardial infarction, function and viability assessed with CMR in patients with a CTO. The findings were additionally related to the presence of WD and PD collaterals on invasive coronary angiography. The infarcted area in the CTO territory was generally limited with extensive scar observed in only 5% of CTO segments. Well-developed collaterals were associated with less scar and more preserved function in myocardium subtended by a CTO. Myocardial viability in the CTO territory with potential to functionally recover after revascularization, in this study represented by dysfunctional myocardium without extensive scar, was more extensive in patients with PD collaterals.

Documented history of MI and scar tissue on contrast-enhanced CMR

Choi et al. demonstrated earlier that LV scar tissue is present in a much larger proportion (86%) of patients with a CTO than clinically recognized[7]. The current study primarily focused on LGE quantification specifically in the CTO territory and revealed myocardial scar in the CTO

region in 76% of patients without a documented CTO vessel-related history of MI. However, infarct sizes were often small with 95% of CTO segments demonstrating no or limited scar tissue. In clinical practice, it is regularly assumed that a history of MI related to the CTO territory, especially in the presence of pathological Q-waves, excludes myocardium without transmural scar. This assumption seems to be inappropriate in the vast majority of patients according to this study.

Myocardial infarction and function related to the degree of collateral development

A previous study showed that infarct size after unsuccessful thrombolysis after STEMI was reduced in patients in whom collaterals that supply the infarct-related artery immediately could be visualized on invasive angiography[13]. Wustmann et al. additionally demonstrated that the immediate well-functioning of the collateral system after brief vascular occlusion, as invasively measured with the collateral flow index, differs to a great extent between individuals with one fifth showing no signs of ischemia[14]. These results raise the question if collateral systems with a comparable angiographic appearance in patients with a CTO could have had variable protective effects on myocardial contractility in the past, especially if the CTO lesion developed from an untreated acute thrombotic event. In addition, collateral blood supply to myocardium subtended by a CTO could hypothetically be limited in patients with multivessel disease due to obstructive disease in another coronary artery proximal to the origin of the collateral. Nevertheless, when a CTO is depicted by diagnostic angiography in clinical practice, a protective role is regularly allocated to WD collaterals supplying a CTO territory, while a lack of myocardial preservation is imposed to PD collaterals. These assertions are substantiated by the present study, which demonstrated that patients with WD collaterals had less myocardial scar and more retained myocardial function in the CTO territory consistent with a few smaller studies[6,7]. However, the present study additionally suggests that stratification by collateral

status in the individual patient has limited value since regional infarct size was small and myocardial function preserved in the majority of patients with PD collaterals as well. These findings are in line with prior results by Werner et al., whom observed that not the invasively measured collateral function but a lower microvascular resistance in myocardium subtended by a CTO was associated with regional functional improvement after CTO PCI[15].

Viability detection and potential for functional recovery

The randomized REVASC-trial and a recent meta-analysis including 34 observational studies showed a mean increase in LVEF of <5% after successful CTO revascularization[4,5]. The clinical relevance of this modest functional improvement is questionable, especially considering recently published randomized trials showing no superiority in patient' prognosis after CTO PCI compared to medical therapy[1,2]. The results of these trials suggest that invalidating symptoms may be considered the primary indication to refer a patient for CTO PCI. In contrast, a few observational studies demonstrated substantial improvements in LVEF if viability demonstration was included in the clinical decision making[16,17]. A prerequisite for viability is the presence of dysfunctional "hibernating" myocardium. Historically, hibernation is defined as chronic dysfunctional myocardium during a state of chronic hypoperfusion, although some prior data suggested the occurrence of repeated episodes of ischemia rather than chronic hypoperfusion to be the cause of chronic regional wall motion abnormalities in collateral-dependent noninfarcted myocardium[18]. Dysfunctional myocardium suffering from chronic hypoperfusion or repeated episodes of ischemia is expected to functionally improve after revascularization[18]. In contrast, the presence of preserved contractility or extensive myocardial fibrosis before revascularization can result in no or limited functional recovery[11,17]. The current gold standard for myocardial hibernation and viability detection is fluorine-18-deoxyglucose positron emission tomography (FDG-PET), which is

often performed in conjunction with myocardial perfusion imaging to evaluate the presence of perfusion-metabolism mismatches. The choice for CMR as viability test out of several non-invasive imaging modalities in the current study was based on local availability and expertise in this single centre. CMR-derived viability was represented by baseline dysfunctional myocardium without extensive scar, and was scored per segment leading to a more detailed indication of the extent of viability as compared to a per-vessel analysis. Viability was observed in 35% of CTO segments which equals two segments in a standardized vascular territory (consisting of five or six segments) according to the 17-segment model[9]. The relatively preserved LV function and limited amount of viability in the CTO territory substantiate the overall modest improvement in LVEF after CTO PCI in most studies[4]. In addition, a correlation was found between myocardial dysfunction and extent of scar tissue. Consequently, it cannot be genuinely distinguished if the increased myocardial dysfunction (and viability) observed in CTO segments in patients with a prior Q-wave MI or PD collaterals is a marker of enhanced hibernating myocardium or a repercussion of augmented but still limited scar formation. Yet, it should be emphasized that neither PD collaterals nor a documented history of MI exclude viability according to the findings in the present study, and should not be the reason to defer a patient from considerations for CTO revascularization. In these patients as well clinical decision making should take place after careful evaluation of all information regarding symptom severity, viability, and ischemia, as advocated in current guidelines[3].

Limitations

Patients represent a single centre population over the full LVEF range. Extent of scar tissue and dysfunction may therefore be less compared to prior studies with more stringent patient selection for viability assessment. The CMR analysis lacked myocardial perfusion imaging or dobutamine stress testing and therefore cannot genuinely indicate chronic hypoperfusion and

hibernating myocardium. However, a prior study showed that current CMR analyses for myocardial viability assessment hold high accuracy as referenced by FDG-PET[19]. Any patient selection bias by referring physicians from other centres because of the angiographic appearance or location of the CTO lesion cannot be ruled out. The intraobserver and interobserver agreements of visual collateral classification were modest, reflecting the difficulty to grade collaterals qualitatively. Invasive assessment of collateral function was not performed and could add in exploring relationships between collateral function and myocardial viability. Coronary anatomy is known to vary and subtle discordances with standardized myocardial segmentation cannot be excluded.

CONCLUSION

Although myocardial scar is commonly observed in patients with a CTO, infarct sizes are generally limited in the CTO territory. Well-developed collaterals are associated with less scar and more preserved function in myocardium subtended by a CTO. Extent of myocardial viability with potential for functional recovery in patients with a CTO seems to be modest, however, PD collaterals nor a CTO-vessel related history of MI exclude the presence of viability. Neither PD collaterals nor a history of MI related to the CTO territory should be a reason to defer a patient from considerations for CTO revascularization.

IMPACT ON DAILY PRACTICE

In the present study, the infarcted area in myocardium subtended by a CTO was generally limited, even in patients with a documented history of MI. Although differences were small, well-developed collaterals were associated with less myocardial scar and enhanced preserved function. However, myocardial viability was regularly present in patients with poorly-developed collaterals as well. These results show that patients with a CTO should not be

deferred from considerations for CTO revascularization based on the presence of poorly-developed collaterals or a CTO artery-related history of MI.

FUNDING

None

CONFLICTS OF INTEREST

The authors have no conflicts of interest to declare.

Copyright EuroIntervention

REFERENCES

1. Werner GS, Martin-Yuste V, Hildick-Smith D, Boudou N, Sianos G, Gelev V, Rumoroso JR, Erglis A, Christiansen EH, Escaned J, di Mario C, Hovasse T, Teruel L, Bufe A, Lauer B, Bogaerts K, Goicolea J, Spratt JC, Gershlick AH, Galassi AR, Louvard Y and investigators Et. A randomized multicentre trial to compare revascularization with optimal medical therapy for the treatment of chronic total coronary occlusions.*Eur Heart J*.2018 7;39(26):2484-2493.
2. Lee SW, Lee PH, Ahn JM, Park DW, Yun SC, Han S, Kang H, Kang SJ, Kim YH, Lee CW, Park SW, Hur SH, Rha SW, Her SH, Choi SW, Lee BK, Lee NH, Lee JY, Cheong SS, Kim MH, Ahn YK, Lim SW, Lee SG, Hiremath S, Santoso T, Udayachalerm W, Cheng JJ, Cohen DJ, Muramatsu T, Tsuchikane E, Asakura Y and Park SJ. Randomized Trial Evaluating Percutaneous Coronary Intervention for the Treatment of Chronic Total Occlusion.*Circulation*.2019;139:1674-1683.
3. Neumann FJ, Sousa-Uva M, Ahlsson A, Alfonso F, Banning AP, Benedetto U, Byrne RA, Collet JP, Falk V, Head SJ, Juni P, Kastrati A, Koller A, Kristensen SD, Niebauer J, Richter DJ, Seferovic PM, Sibbing D, Stefanini GG, Windecker S, Yadav R and Zembala MO. 2018 ESC/EACTS Guidelines on myocardial revascularization.*Eur Heart J*.2019;40:87-165.
4. Megaly M, Saad M, Tajti P, Burke MN, Chavez I, Gossel M, Lips D, Mooney M, Poulou A, Sorajja P, Traverse J, Wang Y, Kohl LP, Bradley SM and Brilakis ES. Meta-analysis of the impact of successful chronic total occlusion percutaneous coronary intervention on left ventricular systolic function and reverse remodeling.*J Interv Cardiol*.2018;31:562-571.
5. Mashayekhi K, Nuhrenberg TG, Toma A, Gick M, Ferenc M, Hochholzer W, Comberg T, Rothe J, Valina CM, Löffelhardt N, Ayoub M, Zhao M, Bremicker J, Jander N, Minners J, Ruile P, Behnes M, Akin I, Schaufele T, Neumann FJ and Buttner HJ. A Randomized Trial to

Assess Regional Left Ventricular Function After Stent Implantation in Chronic Total Occlusion: The REVASC Trial.*JACC Cardiovasc Interv.*2018;11:1982-1991.

6. Ripley DP, Gosling OE, Bhatia L, Peebles CR, Shore AC, Curzen N and Bellenger NG. The relationship between the contralateral collateral supply and myocardial viability on cardiovascular magnetic resonance: can the angiogram predict functional recovery?*Int J Cardiol.*2014;177:362-7.

7. Choi JH, Chang SA, Choi JO, Song YB, Hahn JY, Choi SH, Lee SC, Lee SH, Oh JK, Choe Y and Gwon HC. Frequency of myocardial infarction and its relationship to angiographic collateral flow in territories supplied by chronically occluded coronary arteries.*Circulation.*2013;127:703-9.

8. Werner GS, Ferrari M, Heinke S, Kuethe F, Surber R, Richartz BM and Figulla HR. Angiographic assessment of collateral connections in comparison with invasively determined collateral function in chronic coronary occlusions.*Circulation.*2003;107:1972-7.

9. Cerqueira MD, Weissman NJ, Dilsizian V, Jacobs AK, Kaul S, Laskey WK, Pennell DJ, Rumberger JA, Ryan T and Verani MS. Standardized myocardial segmentation and nomenclature for tomographic imaging of the heart. A statement for healthcare professionals from the Cardiac Imaging Committee of the Council on Clinical Cardiology of the American Heart Association.*Circulation.*2002;105:539-42.

10. Nijveldt R, Beek AM, Hirsch A, Stoel MG, Hofman MB, Umans VA, Algra PR, Twisk JW and van Rossum AC. Functional recovery after acute myocardial infarction: comparison between angiography, electrocardiography, and cardiovascular magnetic resonance measures of microvascular injury.*J Am Coll Cardiol.*2008;52:181-9.

11. Romero J, Xue X, Gonzalez W and Garcia MJ. CMR imaging assessing viability in patients with chronic ventricular dysfunction due to coronary artery disease: a meta-analysis of prospective trials.*JACC Cardiovasc Imaging.*2012;5:494-508.

12. Bondarenko O, Beek AM, Nijveldt R, McCann GP, van Dockum WG, Hofman MB, Twisk JW, Visser CA and van Rossum AC. Functional outcome after revascularization in patients with chronic ischemic heart disease: a quantitative late gadolinium enhancement CMR study evaluating transmural scar extent, wall thickness and periprocedural necrosis. *J Cardiovasc Magn Reson*.2007;9:815-21.
13. Habib GB, Heibig J, Forman SA, Brown BG, Roberts R, Terrin ML and Bolli R. Influence of coronary collateral vessels on myocardial infarct size in humans. Results of phase I thrombolysis in myocardial infarction (TIMI) trial. The TIMI Investigators. *Circulation*.1991;83:739-46.
14. Wustmann K, Zbinden S, Windecker S, Meier B and Seiler C. Is there functional collateral flow during vascular occlusion in angiographically normal coronary arteries? *Circulation*.2003;107:2213-20.
15. Werner GS, Surber R, Kueth F, Emig U, Schwarz G, Bahrmann P and Figulla HR. Collaterals and the recovery of left ventricular function after recanalization of a chronic total coronary occlusion. *Am Heart J*.2005;149:129-37.
16. Galassi AR, Boukhris M, Toma A, Elhadj Z, Laroussi L, Gaemperli O, Behnes M, Akin I, Luscher TF, Neumann FJ and Mashayekhi K. Percutaneous Coronary Intervention of Chronic Total Occlusions in Patients With Low Left Ventricular Ejection Fraction. *JACC Cardiovasc Interv*.2017;10:2158-2170.
17. Baks T, van Geuns RJ, Duncker DJ, Cademartiri F, Mollet NR, Krestin GP, Serruys PW and de Feyter PJ. Prediction of left ventricular function after drug-eluting stent implantation for chronic total coronary occlusions. *J Am Coll Cardiol*.2006;47:721-5.
18. Vanoverschelde JL, Wijns W, Depre C, Essamri B, Heyndrickx GR, Borgers M, Bol A and Melin JA. Mechanisms of chronic regional postischemic dysfunction in humans. New

insights from the study of noninfarcted collateral-dependent myocardium.*Circulation*.1993;87:1513-23.

19. Li JN, He Y, Dong W, Zhang LJ, Mi HZ, Zhang DF, Huang RC and Song XT. Comparison of cardiac MRI with PET for assessment of myocardial viability in patients with coronary chronic total occlusion.*Clin Radiol*.2019;74:410e1-410e9.

Copyright EuroIntervention

FIGURE LEGENDS

Figure 1. Median percentage scar tissue (A) and mean SWT (B) in the CTO territory stratified according to collateral status. Cine and LGE analysis could not be performed due to insufficient image quality in two and three patients, respectively. Red lines represent means. CTO, chronic coronary total occlusion; LGE, late gadolinium enhancement; SWT, segmental wall thickening.

Figure 2. Case examples including a patient with WD and PD collaterals. 1A) A WD collateral (arrow) supplies the vascular territory of a CTO in the right coronary artery. Two-chamber and short-axis views at end-diastolic (1B, 1C) and end-systolic (1D, 1E, arrows) phases show mild hypokinesia of the inferior wall, in the presence of limited subendocardial scar (arrows) detected with LGE (1F, 1G). 2A) PD collaterals supply the vascular territory of a CTO in the left circumflex artery. Four-chamber and short-axis views during end-diastolic (2B, 2C) and end-systolic (2D, 2E) phases display moderate hypokinesia (arrows) of the lateral wall, while LGE (2F, 2G) demonstrates a considerable (but still limited) amount of subendocardial scar (arrows). PD, poorly-developed; WD, well-developed; other abbreviations as in figure 1.

Figure 3. The correlation between left ventricular percentage scar and ejection fraction (A), and correlations between percentage scar tissue and SWT per CTO territory (B) and per segment in the CTO territory (C). Abbreviations as in figure 1.

Figure 4. Distribution of CTO segments according to myocardial contractility and (non)extensive scar formation. Numbers below the horizontal axis represent number of

segments. A) CTO segments in all patients and in subgroups of patients stratified according to
Disclaimer : As a public service to our readership, this article -- peer reviewed by the Editors of EuroIntervention - has been published immediately upon acceptance as it was received. The content of this article is the sole responsibility of the authors, and not that of the journal

documented CTO vessel-related history of MI and presence (or absence) of scar in the CTO territory on CMR. B) Percentage of segments demonstrating viability with potential for functional recovery, compared between subgroups. C) Distribution of CTO segments according to collateral status. D) Percentage of segments demonstrating viability with potential for functional recovery compared between patients with WD collaterals and PD collaterals. CMR, cardiac magnetic resonance; MI, myocardial infarction; other abbreviations as in figure 1.

Copyright EuroIntervention

Table 1. Clinical characteristics

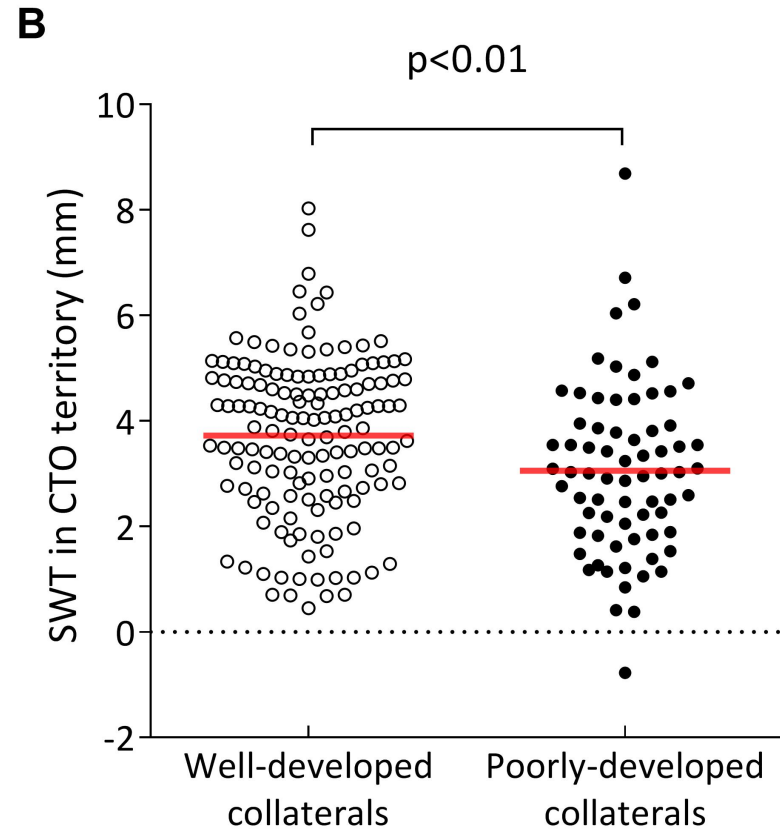
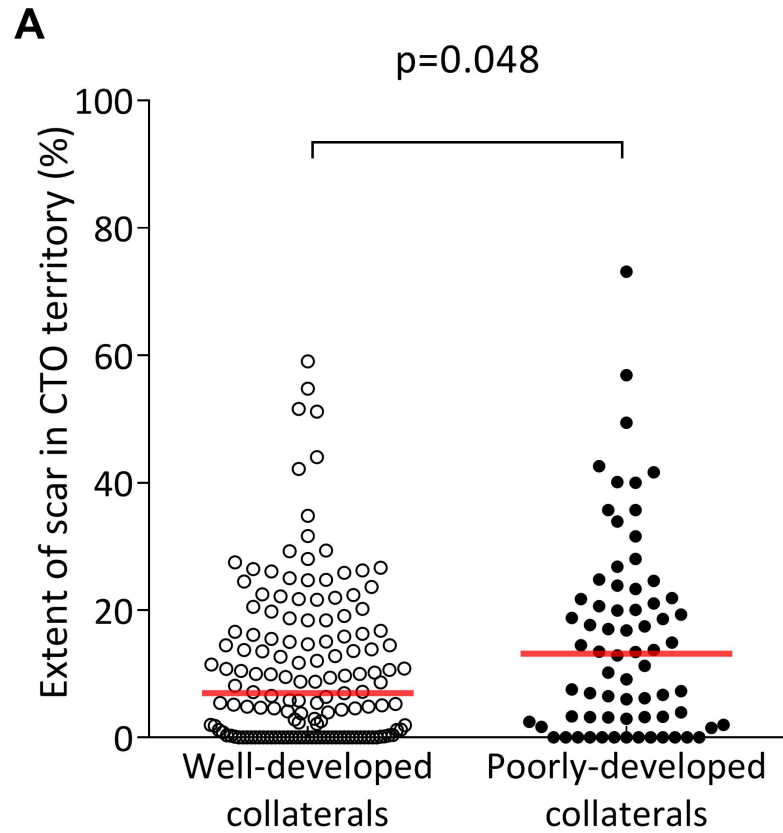
	All patients	Well-developed collaterals	Poorly-developed collaterals	p Value
	N = 218	N = 146	N = 72	
Age (years)	63±10	63±11	63±10	0.73
Male	170 (78)	110 (75)	60 (83)	0.22
Body Mass Index (kg·m ⁻²)	28±4	28±5	28±4	0.49
Prior MI	118 (54)	73 (50)	45 (63)	0.09
CTO territory	71 (33)	38 (26)	33 (46)	<0.01
Q-wave	41 (19)	21 (14)	20 (28)	0.03
Prior PCI	150 (69)	101 (69)	49 (68)	0.88
CTO territory	40 (18)	29 (20)	11 (15)	0.46
Prior CABG	14 (6)	9 (6)	5 (7)	0.78
Clinical presentation				
Free of symptoms*	46 (21)	32 (22)	14 (19)	0.73
Stable angina	143 (66)	96 (66)	47 (65)	1.00
Acute coronary syndrome	2 (1)	2 (1)	0 (0)	1.00
Other**	27 (12)	16 (11)	11 (15)	0.39

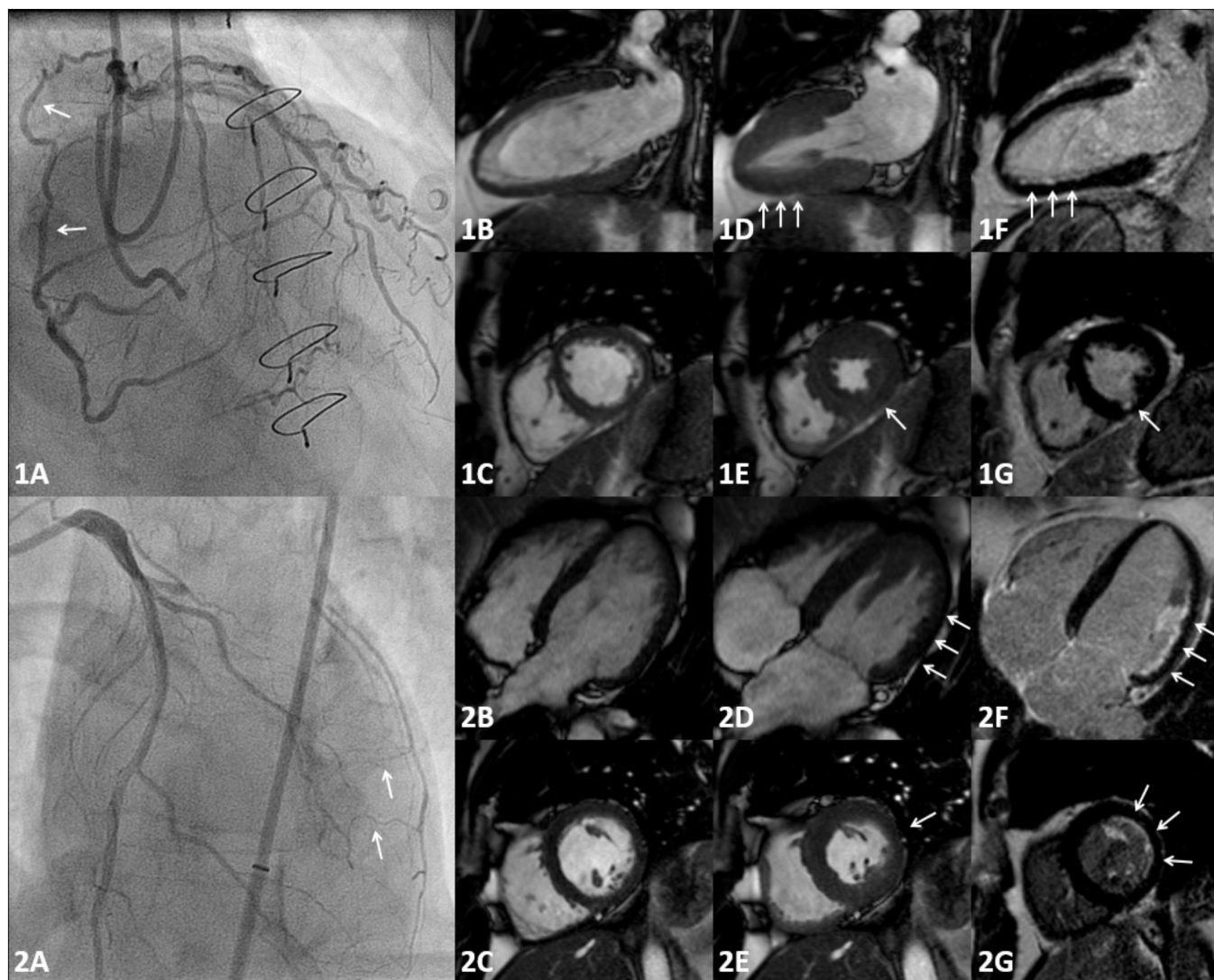
Values are mean ± SD, median [Q1-Q3] or numbers (%). *Patients had become asymptomatic after prior PCI of a non-occluded vessel whilst a CTO lesion still remained. **Ventricular arrhythmia, acute heart failure, and deterioration of left ventricular function during routine control, in 12 (6%), 1 (0%), and 14 (6%) patients, respectively. CABG, coronary artery bypass graft surgery; CTO, chronic coronary total occlusion, MI, myocardial infarction; PCI, percutaneous coronary intervention.

Table 2. CMR imaging

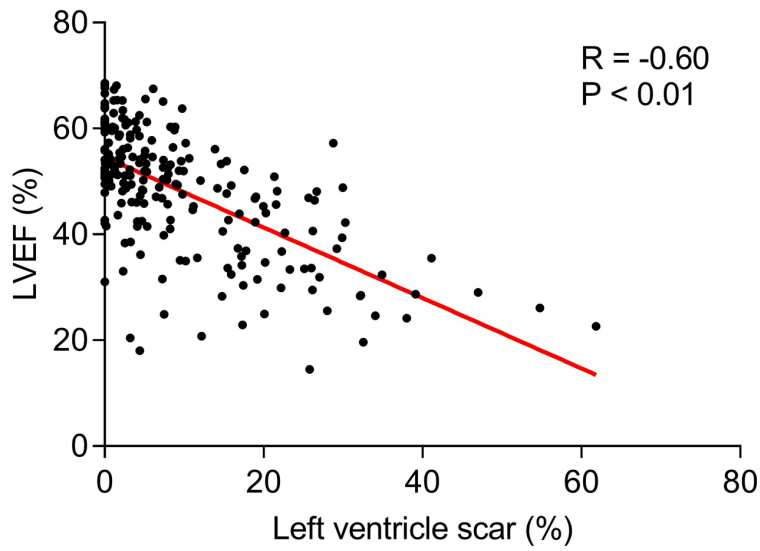
	All patients	Well-developed	Poorly-developed	
		collaterals	collaterals	
	N = 218	N = 146	N = 72	p Value
Left ventricle				
Ejection fraction (%)	48.0±11.8	49.3±11.6	45.4±12.0	0.02
End-diastolic volume (ml)	101.1±33.9	97.9±31.6	107.6±37.4	0.047
End-systolic volume (ml)	55.6±31.6	52.4±29.4	62.1±35.1	0.03
Scar tissue (%)	5.1 [1.5-15.4]	4.6 [1.3-10.2]	7.9 [1.7-19.5]	0.04
CTO territory				
Segmental wall thickening (mm)	3.50±1.57	3.72±1.51	3.05±1.60	<0.01
End-diastolic wall thickness (mm)	6.60±1.64	6.68±1.75	6.43±1.38	0.30
End-systolic wall thickness (mm)	10.10±2.46	10.40±2.55	9.48±2.17	<0.01
Scar tissue (%)	8.6 [0.4-19.8]	7.0 [0.1-16.7]	13.1 [2.8-22.2]	0.048

Values are mean ± SD or median [Q1-Q3]. In two patients no cine images were available due to poor image quality. In three patients no late gadolinium enhancement images were available due to poor image quality (two patients) or lack of performance (one patient). CMR, cardiac magnetic resonance; other abbreviations as in table 1.

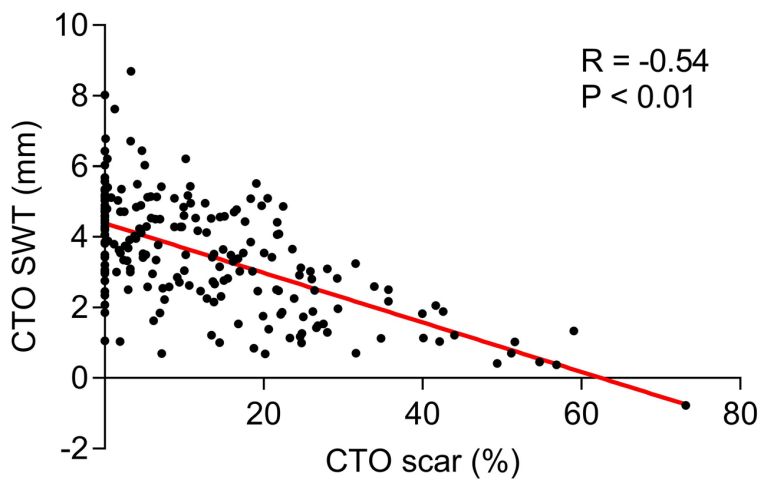




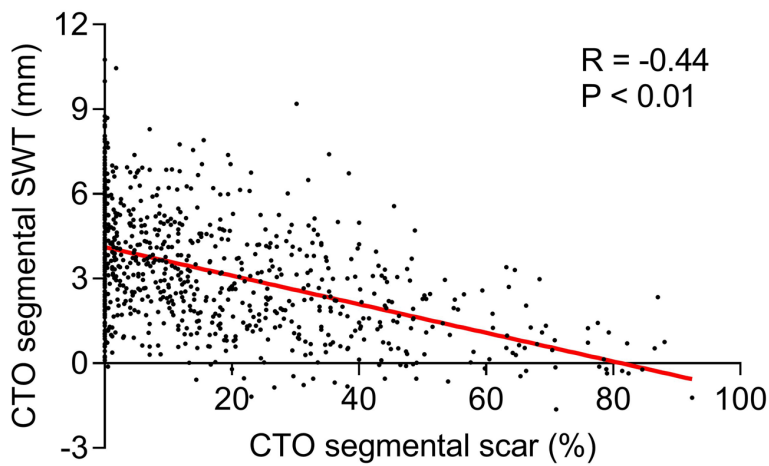
A



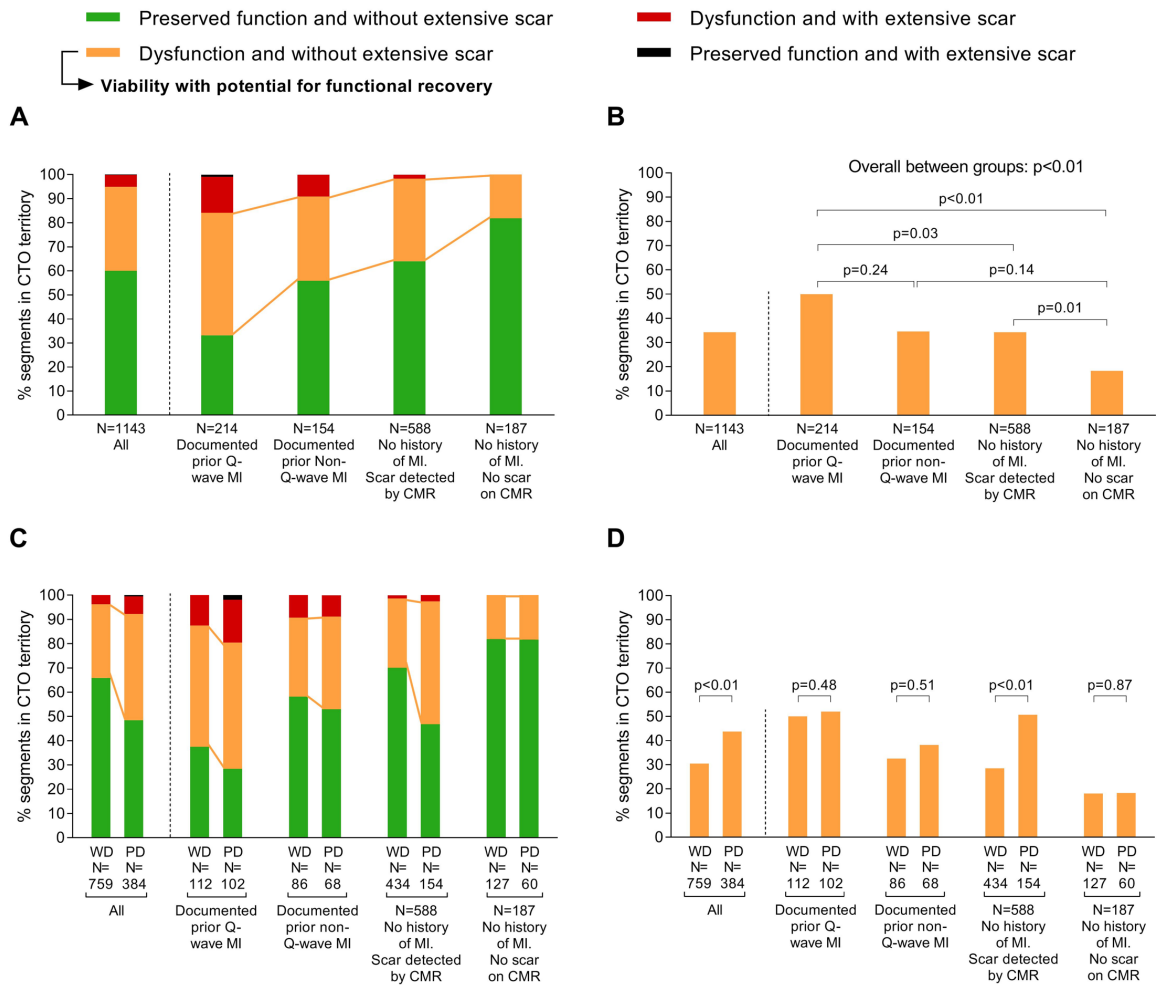
B



C



Viability in the CTO territory



SUPPLEMENTARY MATERIALS

Methods: CMR imaging acquisition

Cine imaging was performed using a steady-state-free precession sequence in three long-axis and multiple contiguous short-axis views encompassing the entire left ventricle (LV) from base to apex. Typical parameters were: spatial resolution, 1.6 x 1.6 mm²; slice thickness/gap, 5/5 mm; repetition/echo time, 3.2/1.5 ms; α , 60-80°; temporal resolution, 30-50 ms. LGE was performed 10-15 minutes after administration of 0.2 mmol/kg of a gadolinium-based contrast agent (DOTAREM®, Guerbet, Villepinte, France), using a segmented inversion recovery gradient-echo pulse sequence. Slice positions were identical to the cine images. Typical parameters were: spatial resolution, 1.6 x 1.6 mm², slice thickness 5 mm, repetition /echo time 9.6/4.4 ms; α , 25°; inversion time, 250-300 ms nulled to normal myocardium.

Supplementary table 1. Cardiac risk factors and medication

	All patients	Well-developed collaterals	Poorly-developed collaterals	p Value
	N = 218	N = 146	N = 72	
Cardiac risk factors				
Hypertension	111 (51)	71 (49)	40 (56)	0.39
Hypercholesterolemia	89 (41)	59 (40)	30 (42)	0.88
Current smoking	71 (33)	46 (32)	25 (35)	0.65
History of smoking	83 (38)	54 (37)	29 (40)	0.66
Family history CAD	101 (46)	65 (45)	36 (50)	0.47
Diabetes	50 (23)	34 (23)	16 (22)	1.00
Number cardiac risk factors	2 [1-3]	2 [1-3]	2 [2-3]	0.35
Medication				
Aspirin	194 (89)	132 (90)	62 (86)	0.36
Dual anti-platelets	131 (60)	89 (61)	42 (58)	0.77
Statins	182 (83)	124 (85)	58 (81)	0.44
Beta-blockers	164 (75)	110 (75)	54 (75)	1.00
Calcium channel blockers	50 (23)	35 (24)	15 (21)	0.73
Long-acting nitrates	37 (17)	29 (20)	8 (11)	0.13

Values are median [IQR] or numbers (%). CAD, coronary artery disease.

Supplementary table 2. Angiographic characteristics

	All patients	Well-developed	Poorly-developed	
		collaterals	collaterals	
	N = 218	N = 146	N = 72	p Value
CTO vessel				<0.01
RCA	149 (68)	110 (75)	39 (54)	
LAD	45 (21)	27 (18)	18 (25)	
LCX	23 (11)	8 (5)	15 (21)	
LM	1 (0)	1 (1)	0 (0)	
CTO characteristics				
Previous attempt	35 (16)	26 (18)	9 (13)	0.43
Blunt cap	81 (37)	55 (38)	26 (36)	0.88
Calcification	122 (56)	90 (62)	32 (44)	0.02
Lesion length ≥ 20 mm	103 (47)	72 (49)	31 (44)	0.47
Tortuosity $>45^\circ$	87 (40)	60 (41)	27 (38)	0.66
J-CTO score	2 [1-3]	2 [1-3]	2 [1-2.75]	0.16
Dominant collateral				0.09
Epicardial	103 (47)	72 (49)	31 (43)	
Septal	61 (28)	34 (23)	27 (38)	
Bridging	54 (25)	40 (27)	14 (19)	
Number vessel disease				0.28
Single vessel	149 (68)	96 (66)	53 (74)	
Multivessel	69 (32)	50 (34)	19 (26)	

Values are numbers (%) or median [Q1-Q3]. CTO, chronic coronary total occlusion; J-CTO, Japanese-CTO score; LAD, left anterior descending artery; LCX, left circumflex artery; LM, left main; RCA, right coronary artery.

Copyright EuroIntervention

Supplementary table 3. CMR imaging results in patients stratified by single or multivessel disease

	Single vessel disease N = 149	Multivessel disease N = 69	p Value
Left ventricle			
Ejection fraction (%)	49.5±11.2	44.9±12.6	<0.01
End-diastolic volume (ml)	96.2±32.5	111.4±34.7	<0.01
End-systolic volume (ml)	51.2±29.5	65.0±34.1	<0.01
Scar tissue (%)	4.5 [1.1-10.1]	8.1 [2.7-19.2]	0.02
CTO territory			
Segmental wall thickening (mm)	3.63±1.57	3.24±1.55	0.09
End-diastolic wall thickness (mm)	6.61±1.73	6.59±1.43	0.94
End-systolic wall thickness (mm)	10.2±2.6	9.8±2.1	0.26
Scar tissue (%)	8.6 [0.0-18.7]	8.4 [1.5-21.7]	0.44
Segments with ≤50% LGE	732 (95)	353 (95)	0.48
Dysfunctional segments	282 (36)	173 (47)	0.04
Segments with viability	242 (31)	157 (42)	0.01

Values are mean ± SD or median [Q1-Q3], or numbers (%). In two patients no cine images were available due to poor image quality. In three patients no late gadolinium enhancement images were available due to poor image quality (two patients) or lack of performance (one patient). CMR, cardiac magnetic resonance; LGE, late gadolinium enhancement; other abbreviations as in supplementary table 2.

Supplementary table 4. Segments in the CTO territory with $\leq 50\%$ LGE, dysfunctional myocardium, and viability.

	All	Documented prior Q- wave MI	Documented prior non-Q- wave MI	No history of MI Scar detected by CMR	No history of MI No scar on CMR
	N=1143	N=214	N=154	N=588	N=187
$\leq 50\%$ LGE	1085 (95%)	180 (84%)	140 (91%)	578 (98%)	187 (100%)
Dysfunctional	455 (40%)	141 (66%)	68 (44%)	212 (36%)	34 (18%)
Viability	399 (35%)	109 (51%)	54 (35%)	202 (34%)	34 (18%)

Values are numbers (%). MI, myocardial infarction; other abbreviations as in supplementary table 2 and 3.